

A POSSIBLE PROTECTIVE EFFECTS OF THE CALCIUM CHANNEL BLOCKER (LACIDIPINE) IN CYCLOSPORINE INDUCED NEPHROTOXICITY IN ADULT ALBINO RATS.

Essam, M. Eid (M.D.) and Saadia, A. Shalaby (M.D.)

Department of Anatomy. Benha faculty of medicine. Zagazig university

ABSTRACT

The cyclosporine is now established as the immunosuppressant of choice in human organ transplantation, because it improves graft survival. Unfortunately, the cyclosporine can lead to a wide spectrum of nephrotoxic complications. The aim of this study was to assess the effect of lacidipine (calcium antagonist) on the cyclosporine induced nephrotoxicity in rats. Thirty adult albino rats were used in this study. They were divided into three groups: control group, cyclosporine group and lacidipine treated group. The rats of cyclosporine group were received a dose of 50 mg/kg of body weight for two weeks by daily oral administration. The rats of lacidipine treated group were received the same dose of cyclosporine for 14 days along with lacidipine 1 mg/kg of body weight by daily oral administration three days before and fourteen days concurrently with cyclosporine treatment. At the end of the experiment, there was marked elevation of serum urea and creatinine levels in the cyclosporine group. Lacidipine treatment significantly ($P < 0.05$) reduced the elevated serum urea and creatinine. In control group, the histological examination of the rat renal cortex showed normal glomeruli and Bowman's capsule. The tubules which were seen in the sections consist mainly of the proximal convoluted tubules and some distal convoluted tubules. The proximal convoluted tubules are lined by columnar cells with rounded nuclei and prominent nucleoli. These cells have many microvilli which form a brush border. The cytoplasm of these cells contains mitochondria, few vesicles and small sized lysosomes. The renal corpuscles and tubules are surrounded by minimal amount of loose connective tissue. In cyclosporine group, the sections of the rat renal cortex showed necrosis of some glomeruli, thickening of the Bowman's capsule and degeneration of some tubules. There are hyaline degeneration of other tubules and marked deposition of condensed amount of connective tissue in the renal interstitium. The cytoplasm of cells lining the proximal tubules contains increased number of lysosomes, many vacuoles and vesicles. Some mitochondria are degenerated. In lacidipine treated group, the lacidipine treatment effectively prevented the cyclosporine induced changes in the renal cortex.

In conclusion: lacidipine can effectively antagonize the renal functional and structural changes induced by cyclosporine in rats

Recommendation : We recommend the use of lacidipine for renal transplant patients using cyclosporine for immune suppression to protect their kidneys from cyclosporine induced nephrotoxicity.

“ INTRODUCTION AND AIM OF THE WORK “

The cyclosporine is a fungal peptide with powerful immunosuppressive activity .It was discovered by Borel and his coworkers in 1976 in the course of screening fungal products for antifungal activity but proved to have a remarkable inhibitory effect on lymphocyte proliferation (Borel, 1994) .Due to its potent immunosuppressive effects, the cyclosporine has improved allograft survival in organ transplantation and has been applied increasingly with considerable clinical benefit in the treatment of autoimmune diseases. Unlike most other immunosuppressive agents, the cyclosporine has no depressant effects on the bone marrow. However, the therapeutic benefits of cyclosporine have been frequently limited by the occurrence of acute and chronic nephrotoxicity, which is the most serious side effect (Rodicio, 2000). The dose-related decrease in renal function with cyclosporine in experimental animals is largely thought to be caused by afferent arteriolar vasoconstriction and by the extremely decreased glomerular filtration rate (Myers, 1986); (Perico and Remuzzi, 1991) and (perico, etal, 1992). Chronic cyclosporine administration leads to loss of proximal tubular epithelial cell integrity and tubular atrophy , a variable interstitial injury with secondary fibrosis and macrophage infiltration (Keown, et al .1992) and (Keown and Stiller, 1995). Lacidipine is a highly vasoselective third- generation calcium antagonist that produces a sustained reduction in elevated blood pressure and a low incidence of adverse effects (Bond, et al .1993). Several studies in patients with chronic renal failure suggest that calcium antagonists are of benefits in reducing or arresting the decline in renal function (Salvi, et al. 1990) and (Rodicio, et al, 1993). In rats isolated glomeruli, the calcium antagonist prevented cyclosporine induced vasoconstriction (Rooth, et al.1987).So the aim of this work is to determine the possible prophylactic effect of lacidipine in cyclosporine induced nephrotoxicity in rats.

“MATERIAL AND METHODS”

This study included thirty adult male albino rats weighting 200-250 gm. They were kept under constant environmental and nutritional conditions throughout the period of the study. The rats were divided into three groups. Each of them consisted of ten rats.

Groups I (control group): Rats of this group were not given any drugs for 17 days during the course of the experiment.

Group II (cyclosporine group): Rats of this group were received only cyclosporine in a dose of 50 mg/kg daily orally for 14 days (Naidu , et al .1999).

A rat weighting 200-250gm was given 10-12.5mgof cyclosporine.

Group III (lacidipine treated group): Rats of this group were given the same dose of cyclosporine for 14 days along with lacidipine 1 mg/kg body weight orally daily, 3 days before and 14 days concurrently with cyclosporine treatment (Krenek, et al, 2001). A rat weighting 200-250 gm was given 0.20-0.25 mg lacidipine.

At the end of the experiment, the rats of all groups were anaesthetized with ether. Blood sample of about 2ml was drawn from the inner canthus of each rat eye by using microhematocrite capillary tube for estimation of blood area and serum creatinine (Flavio and William, 1983).The abdominal cavity was opened , the kidneys were exposed ,removed and placed in 10% formaline for histopathological examination .The specimens of kidneys from all three groups were dehydrated in ascending grades of alcohol(70%,90%,96% and 100%).After complete dehydration , the specimens were cleared in xylene, impregnated in three changes of soft paraffin wax, each for one hour and then impregnated in three changes of hard paraffin. Finally, the specimens were embedded in hard paraffin .Serial sections 5-7 μ m thick were cut.Some sections were stained with hematoxylin and eosin .While other sections were stained with Masson’s trichrome for demonstration of interstitial tissue, with Periodic Acid Schiff stain (PAS) for evaluation of basement membrane (Drury and Wallington 1980) and (Horbin and Bancroft 1998). For electron microscopy, after 20 hours of fixation, the kidney specimens were washed in cooled 0.015 M Na cacodylate / HCl buffer and post-fixed in 1% osmium tetroxide. The specimens were then dehydrated and embedded in Durcupan . Semithin sections were stained with 1%

toluidine blue and used for orientation in E/M. Ultrathin sections were mounted on the copper grids, stained with 4% uranyl acetate and 2% lead citrate (Hyat, 1986). The sections were examined using Zeis electron microscope.

Drugs :

The cyclosporine was obtained from Sandoz pharmaceutical company in traditional name "Sandimmune syrup". Each 1 ml = 100 mg.

Lacidipine was obtained from Glaxo pharmaceutical company in traditional name Lacipil tablet. Each tablet =2 mg dissolved in 20 ml saline .Each 10 ml =1 mg .

RESLUTS

I -Histopathological examination of the rat kidney:

A- The control group:

The light microscopic study of the renal cortex of the control rat shows normal renal corpuscles, proximal and distal convoluted tubules. Each renal corpuscle appears as rounded structure. It consists of glomerulus and Bowman's capsule .Each glomerulus shows number of capillary loops .The Bowman's capsule consists of visceral layer covering the glomerulus and parietal layer and Bowman's space in between .The wall of parietal layer is composed of simple squamous epithelium resting on the baseinent membrane. The tubules which are seen in the sections consists mainly of proximal convoluted tubules and some distal convoluted tubules .The proximal convoluted tubules are lined by a single layer of columnar or pyramidal cell with rounded nuclei and prominent nucleoli .These cells rest on the basement membrane and have many microvilli which form a brush border , with very narrow lumen. The distal convoluted tubule has a large lumen and not have prominent brush border (fig.1,2,8 & 9) .The renal corpuscles and tubules are surrounded by only minimal amounts of loose connective tissue (fig.13).The electron microscopic study of the lining epithelial cells of the proximal convoluted tubules show rounded nucleus with prominent nucleolus and microvilli. The cytoplasm contains mitochondria, few vesicles and small sized lysosomes. (fig. 16) .

B- The cyclosporine group:-

The cyclosporine induces variable degrees of glomerular and tubular degeneration. Some glomeruli show partial necrosis with intact Bowman's capsule, while others show complete necrosis with intact Bowman's capsule (fig.3 & 4). The basement membrane of the parietal layer in the affected glomeruli shows marked thickening as evidenced in sections stained by PAS stain (fig. 10 & 11). The sections of renal cortex show areas of complete degeneration of some tubules, while other tubules are still intact (fig. 4, 5, 6 & 10). The basement membrane of the tubules is ruptured with degeneration of its lining epithelium (fig. 11). There is large area of structureless acidophilic mass which is called hyalinization which replaces the degenerating tubules (fig.6). There is deposition of more amount of connective tissue in the renal interstitium that surrounds the atrophic renal corpuscles and tubules (fig. 14).The electron microscopic study of the cells of the proximal convoluted tubules show that the cells are manifested by damage of microvilli and partial degeneration of their nuclei. The cytoplasm of these cells contains increased number of large irregular dense lysosomes, many vacuoles and vesicles. Some of mitochondria are degenerated. The lumen of the proximal tubule contains epithelial debris and inflammatory cells (fig. 17, 18 & 19)

C- The lacidipine treated group:

The glomeruli and Bowman's capsules are nearly similar to the control group. The tubules and their basement membranes are intact (fig.7&12) .There is marked reduction in deposition of connective tissue in the interstitium (fig. 15) .The electron microscopic study of the cells of proximal convoluted tubules show that the cells have normal microvilli and normal nucleus with prominent nucleolus ,The cytoplasm contains mitochondria, few lysosomes and vesicles (fig. 20).

II- Blood urea and serum creatinine levels:-

The mean value of blood urea level in control rats is 22.5 ± 1.15 mg/dl. In rats received cyclosporine only, this level is significantly elevated ($P < 0.05$) to reach 50.0 ± 3.58 mg/dl. The mean value of blood urea level in lacidipine treated group is significantly decreased ($P < 0.05$) to 33.1 ± 3.01 mg/dl, in comparison to the

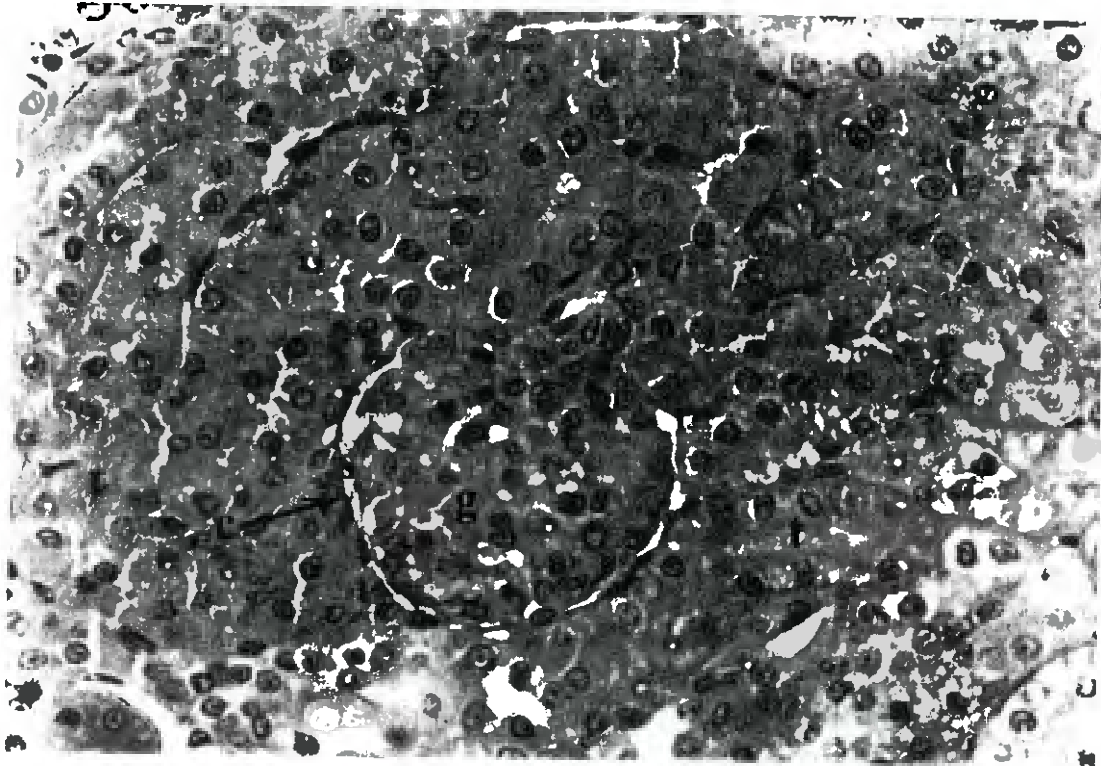
corresponding value of cyclosporine rats. The mean value of serum creatinine level in control rats is 0.61 ± 0.07 mg/dl. In rats received cyclosporine only, this value is significantly elevated ($P < 0.05$) to reach 1.50 ± 0.13 mg/dl. The mean value of serum creatinine level in lacidipine treated group is significantly decreased ($P < 0.05$) to 0.66 ± 0.09 mg/dl, in comparison to the corresponding value of cyclosporine rats (see the table).

A table shows the mean blood urea and serum creatinine levels in mg/dl in control group, cyclosporine group and lacidipine treated group.

Studied group	Group I	Group II	Group III
	Control group	Cyclosporine group	Lacidipine treated group
Blood urea level (mg/dl)	22.5 ± 1.15	50.5 ± 3.058 P<0.05	33.1 ± 3.01 (P) <0.05
Serum Creatinine level (mg/dl)	0.61 ± 0.07	1.50 ± 0.13 P<0.05	0.66 ± 0.09 (P) <0.05

P: cyclosporine group compared to control group.

(P): lacidipine treated group compared to cyclosporine group.



Fig(1) :A photomicrograph of a section of renal cortex of adult control rat showing : Renal corpuscle with normal glomerulus (g) which is surrounded by Bowman's space (s) and capsule (c).It also shows the convoluted tubules (t) with normal appearance (H. & E. X 400)

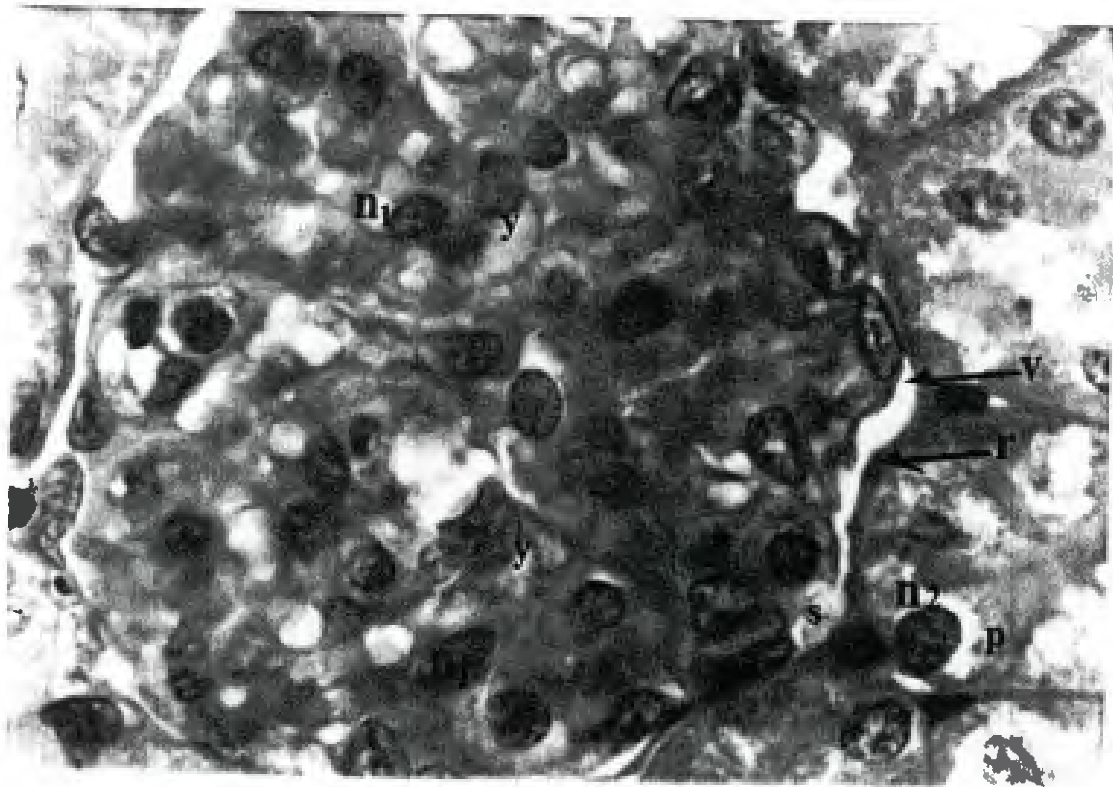


Fig (2) ; A photomicrograph of a high magnification of the previous section showing : The glomerulus consists of network of capillary loops (y) containing nuclei (n1) of blood cells .The glomerulus is surrounded by visceral layer (v) and parietal layer(r) of Bowman's capsule with urinary space (s) in between .It also shows pyramidal cells of the proximal convoluted tubules (p) . These cells have large , rounded nuclei (n2) with prominent nucleolus . (H .&E. oil X 1000)

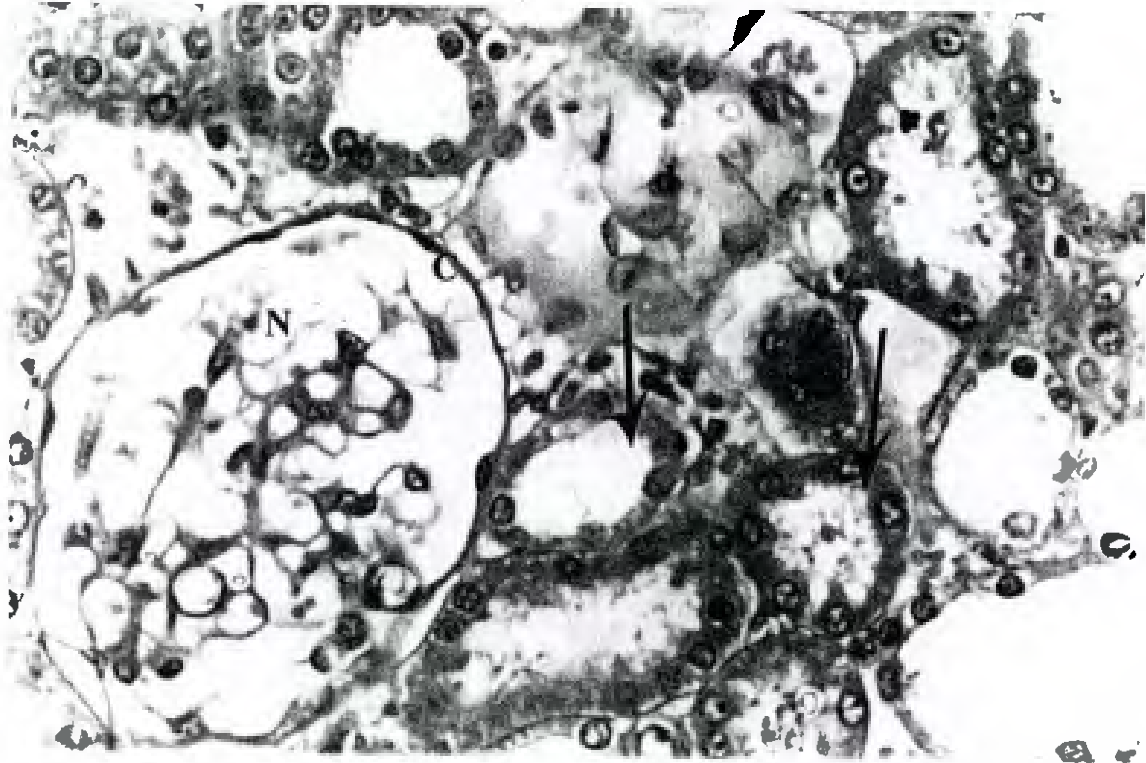


Fig .(3) :A photomicrograph of a section of renal cortex of cyclosporine group showing :partial necrosis (N) of the glomerulus with intact Bowman's capsule (c). Some convoluted tubules are degenerated (d) , while the others are intact (arrows).
(H.&E. X 400)

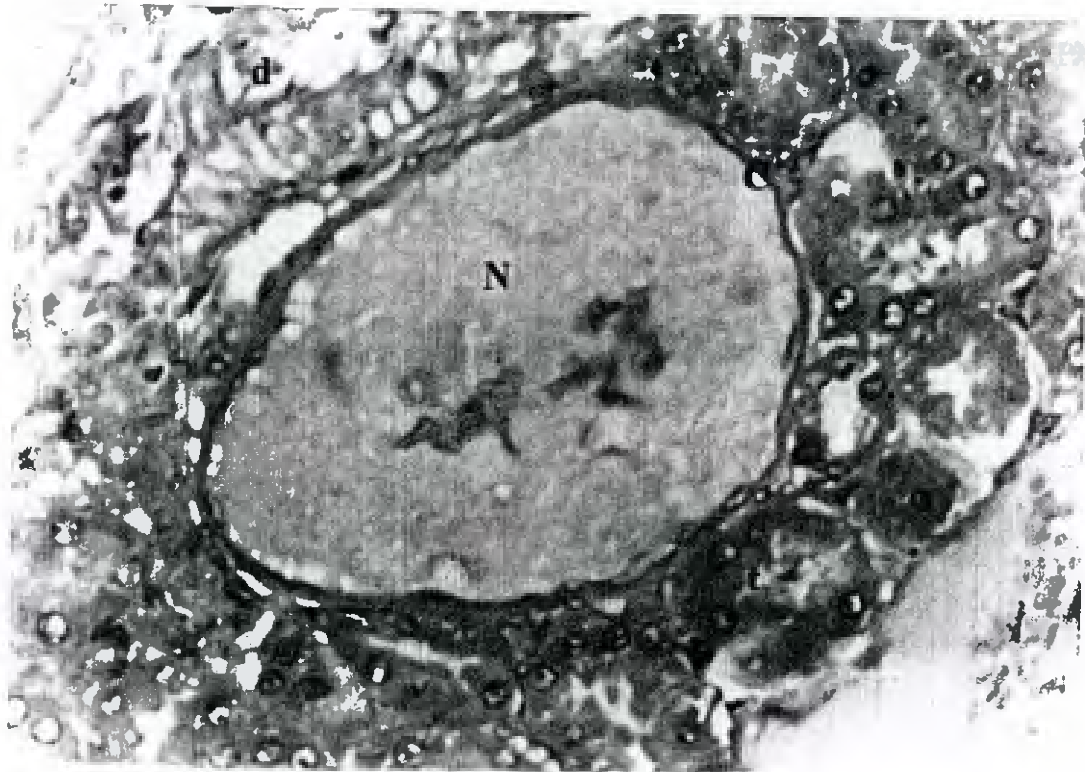

Fig .(4) :A photomicrograph of a section of renal cortex of cyclosporine group showing : Complete necrosis (N) of the glomerulus with intact Bowman's capsule (c) It also shows areas of complete degeneration (d) of some tubules .Note others tubules (t) are still intact .
(H.&E. X400)

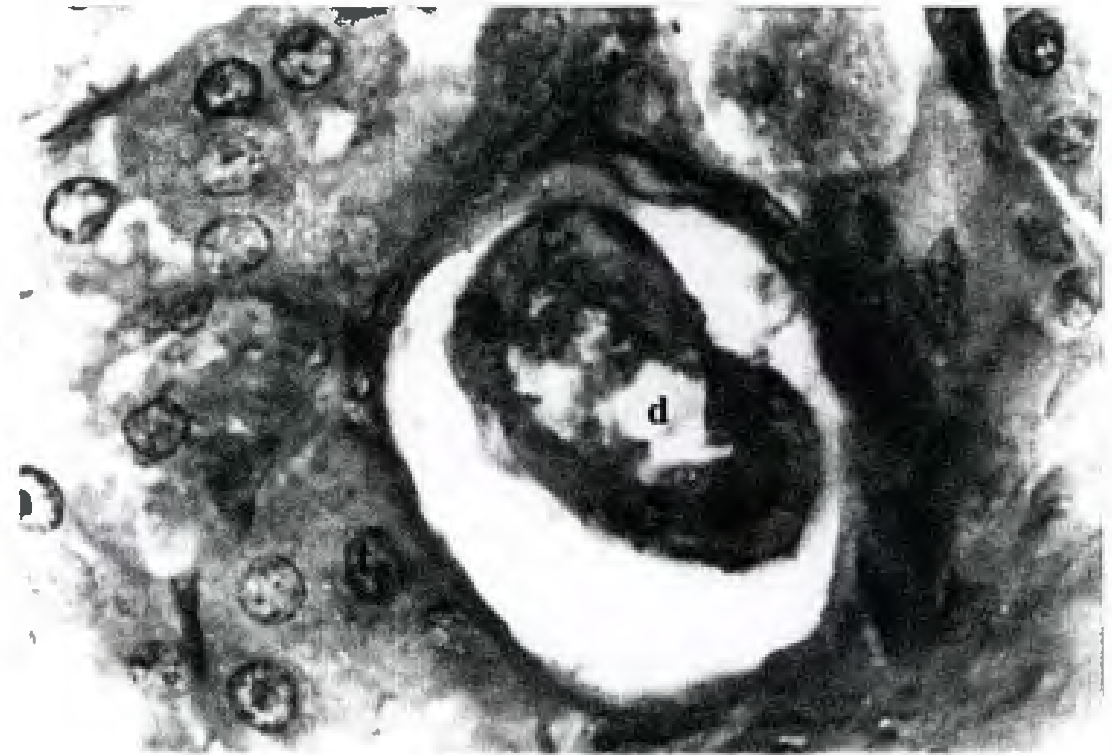


Fig .(5) : A photomicrograph of a section of renal cortex of cyclosporine group showing : Degeneration (d) of the epithelial lining the convoluted tubules .some tubules (t) are still intact .
 (H. &E. oil X1000)

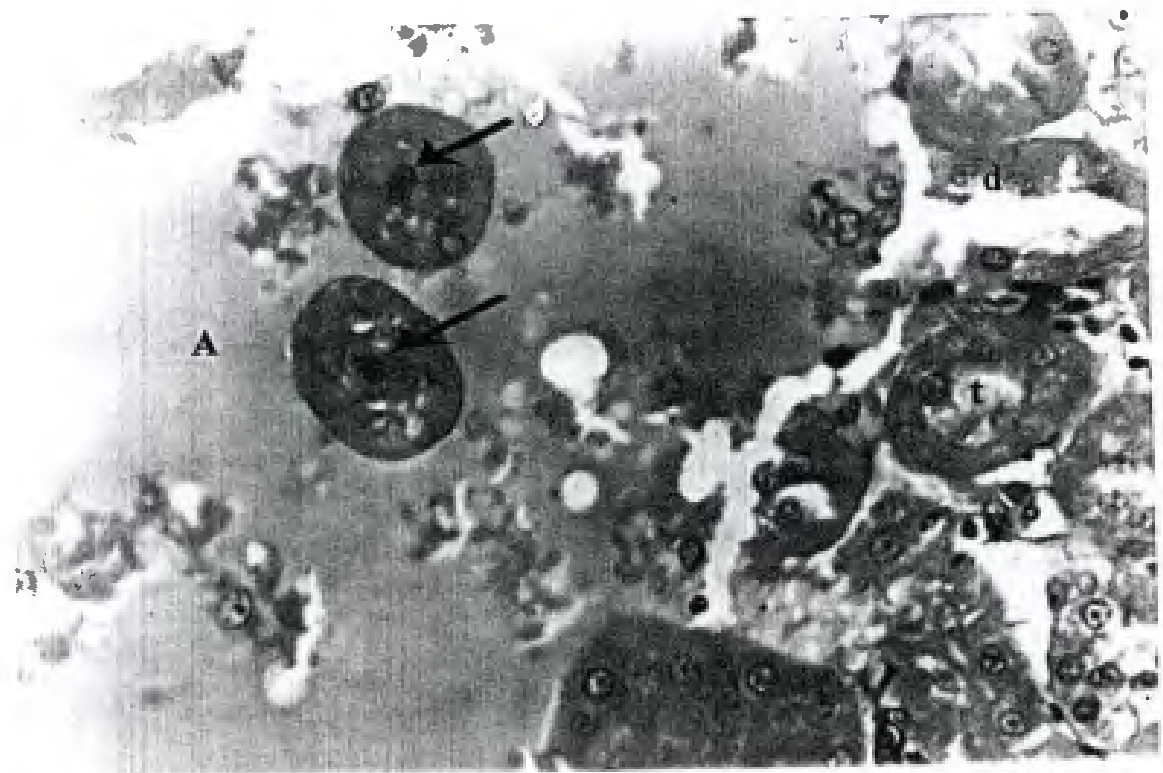


Fig (6) : A photomicrograph of a section of renal cortex of cyclosporine group showing : large area of structureless acidophilic mass (A) that surrounds the collapsed tubules (d).Some tubules are degenerated (d) while the others are still intact (t).
 (H.&E. X400)

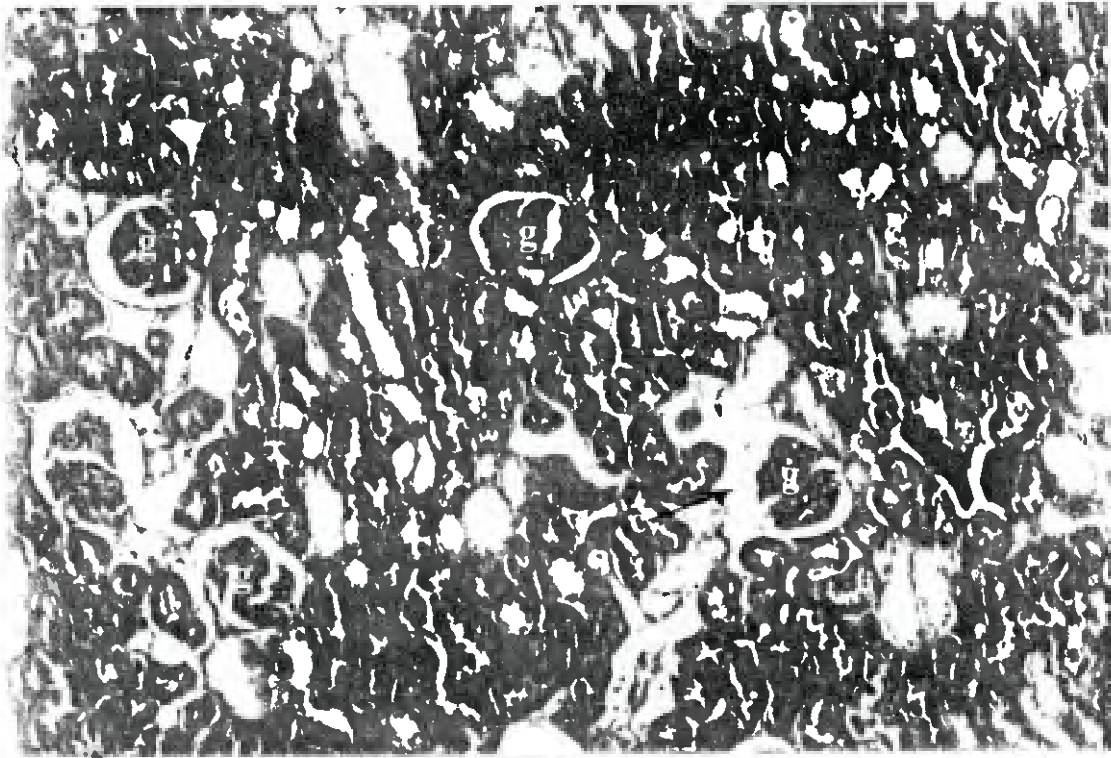


Fig.(7) : A photomicrograph of a section of renal cortex of lacidipine group showing : The glomeruli (g) , Bowman's capsule (c) and the tubules (t) are similar to adult control group .
 (H. &E. X 200)

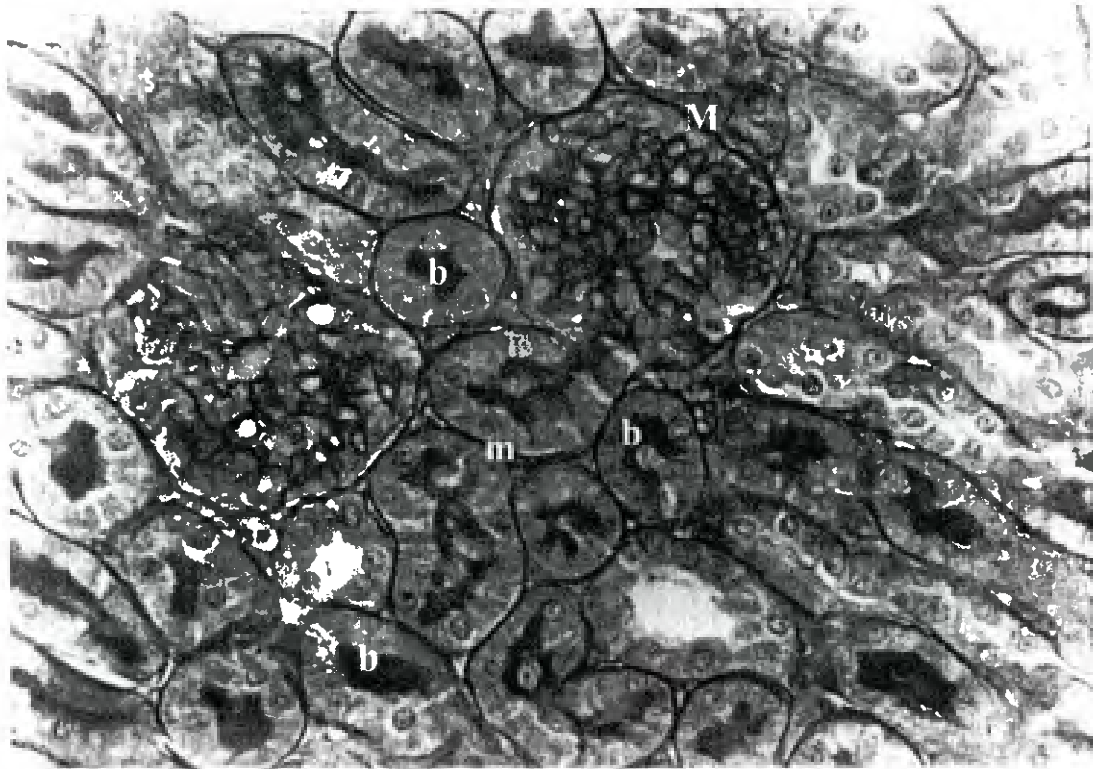


Fig .(8) : A photomicrograph of a section of renal cortex of adult control rat showing .Normal basement membrane (M) of the parietal layer of the Bowman's capsule .The basement membranes (m) of the tubules are normal .The brush border (b) of the proximal tubules are demonstrated by PAS reaction.

(PAS X 400)

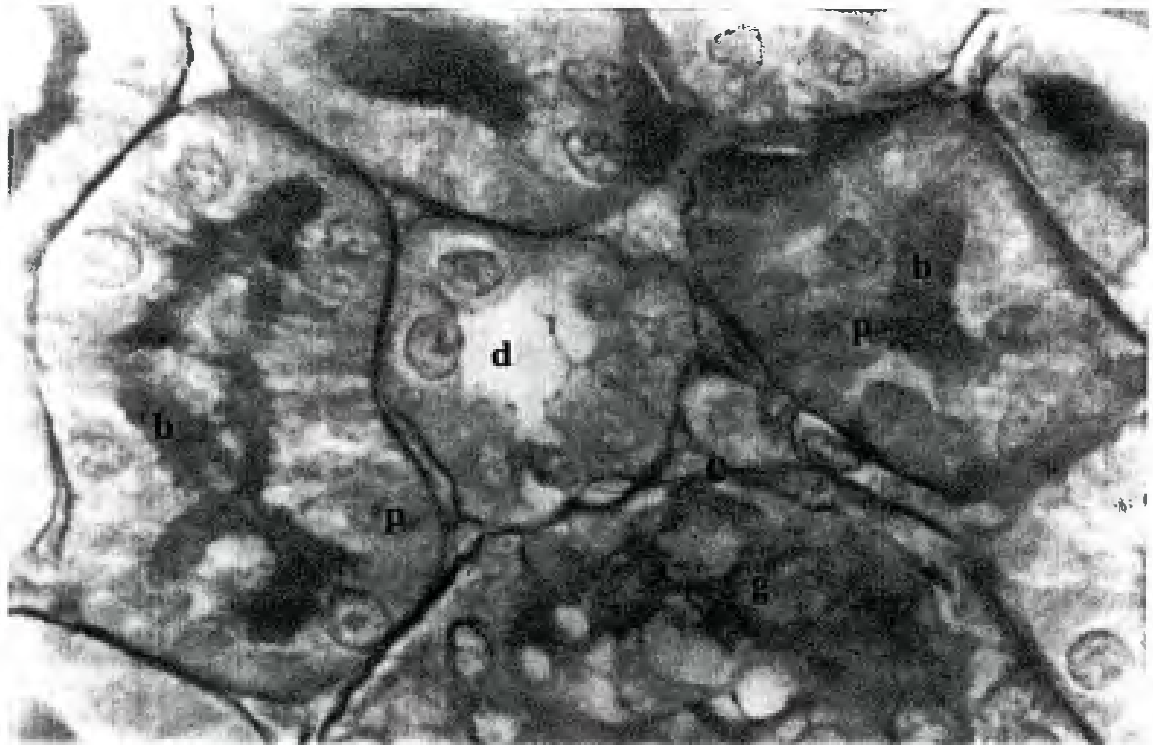


Fig .(9): A photomicrograph of a high magnification of the previous section showing : The proximal convoluted tubules (p) are lined by columnar cells with large , rounded pale nuclei .They have brush border (b) and very narrow lumina .The distal convoluted tubule (d) has large lumen and not have prominent brush border .Notice the part of the glomerulus (g) and Bowman's capsule (c).
(PAS oil X 1000)

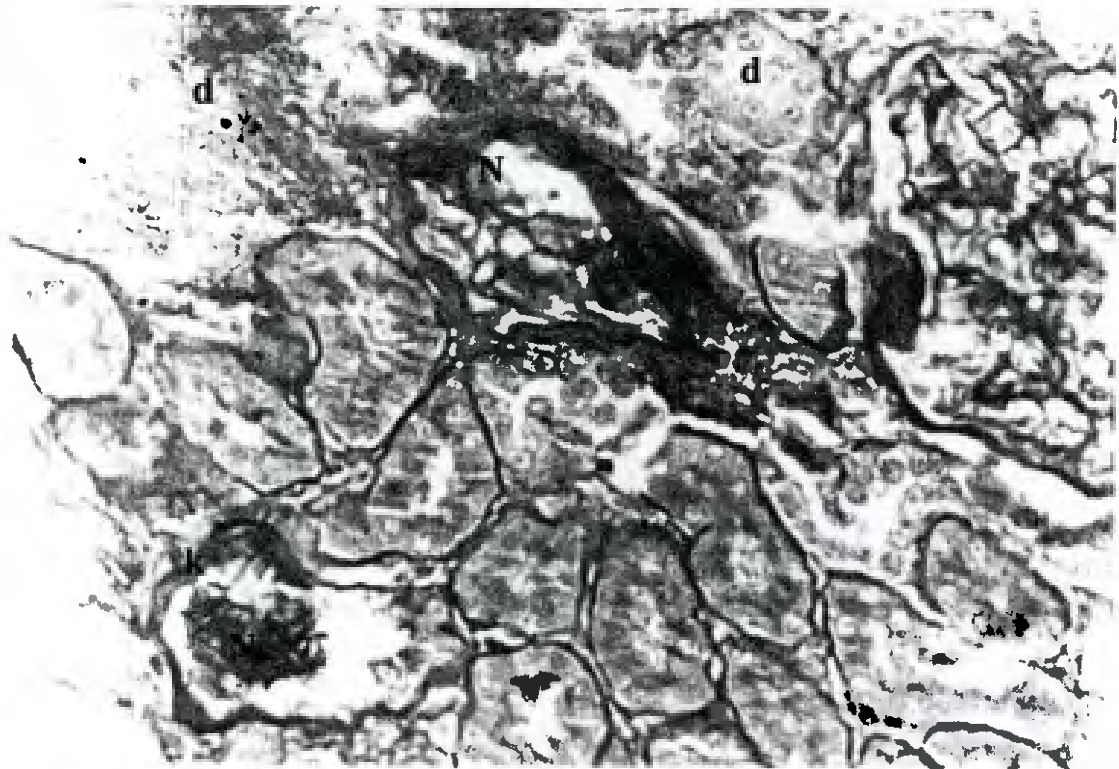


Fig .(10): A photomicrograph of a section of renal cortex of cyclosporine group showing : Necrosis (N) of the glomeruli and marked thickening (K) of the basement membrane of the parietal layer of the Bowman's capsule .Notice the area of complete degeneration (d) of the tubules .
(PAS X 400)

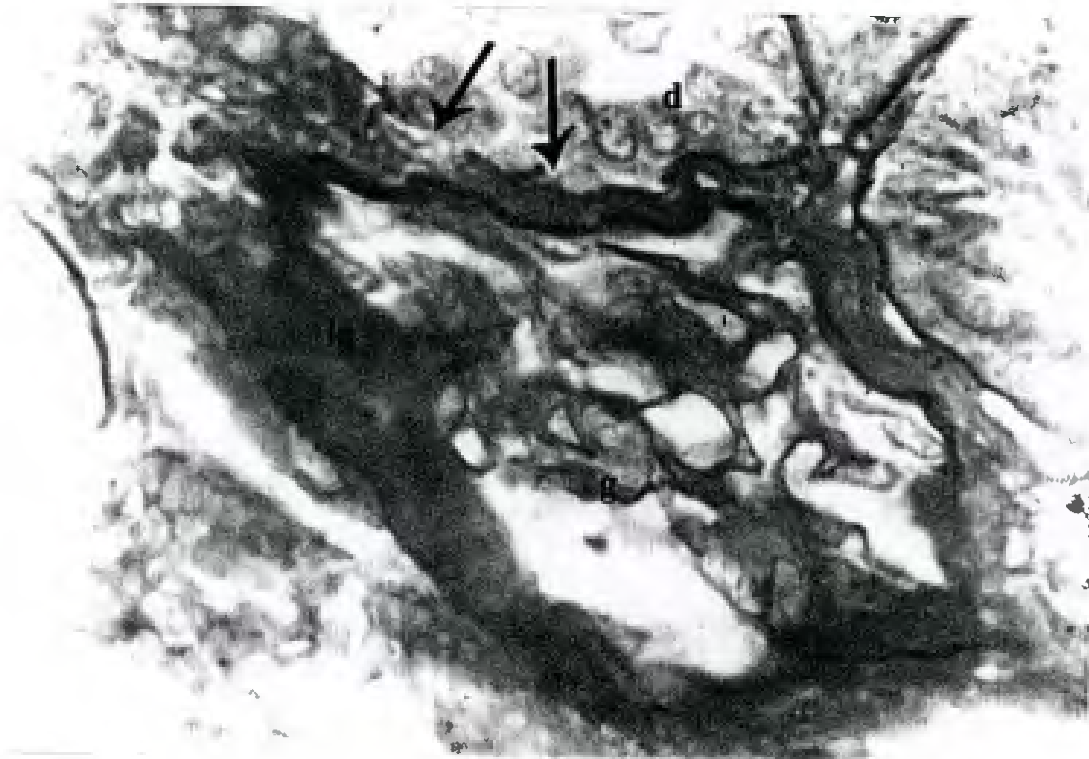

Fig (11): A photomicrograph of a high magnification of the previous section showing :Marked thickening (k) of the basement membrane of the parietal layer of Bowman's capsule. The glomerulus (g) is collapsed with partial necrosis. The basement membrane of the tubules is ruptured (arrows) with degeneration (d) of its lining epithelium.
 (PAS X oil 1000)

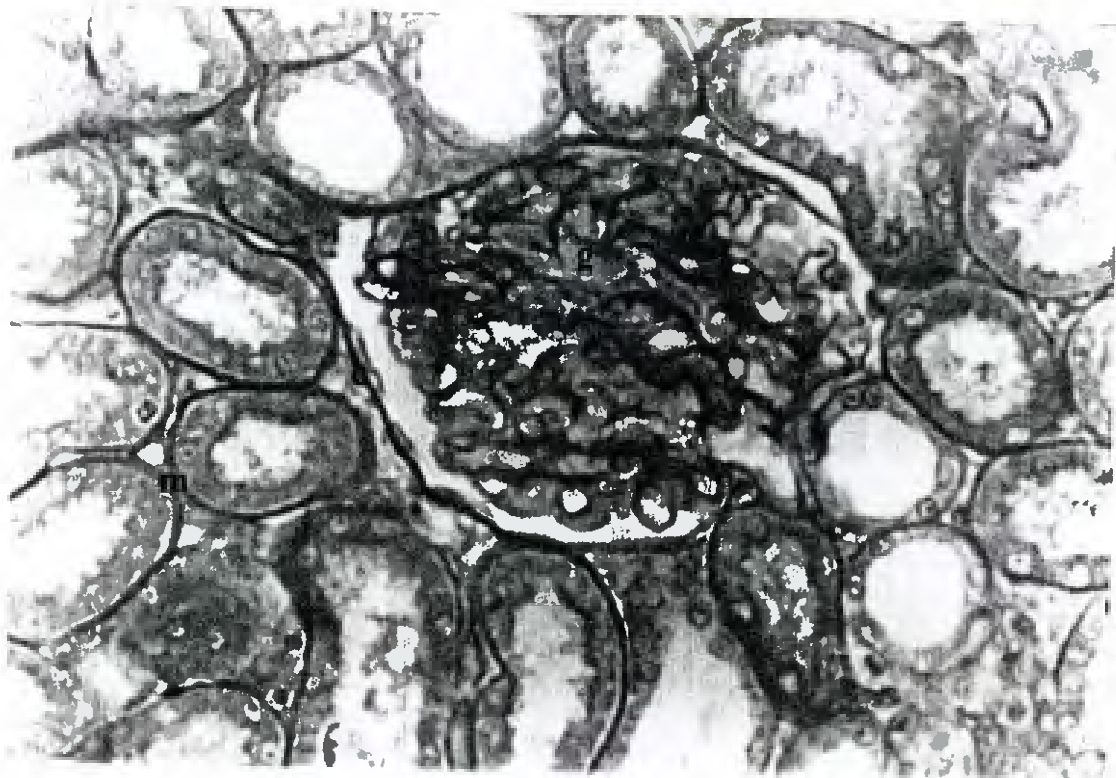


Fig.(12):A photomicrograph of a section of renal cortex of lacidipine group showing :The glomerulus (g) and its Bowman's capsule (c) are similar to the adult control group. The basement membranes (m) of the tubules are intact .their lining epithelium is nearly similar to the control group .

(PAS X 400)

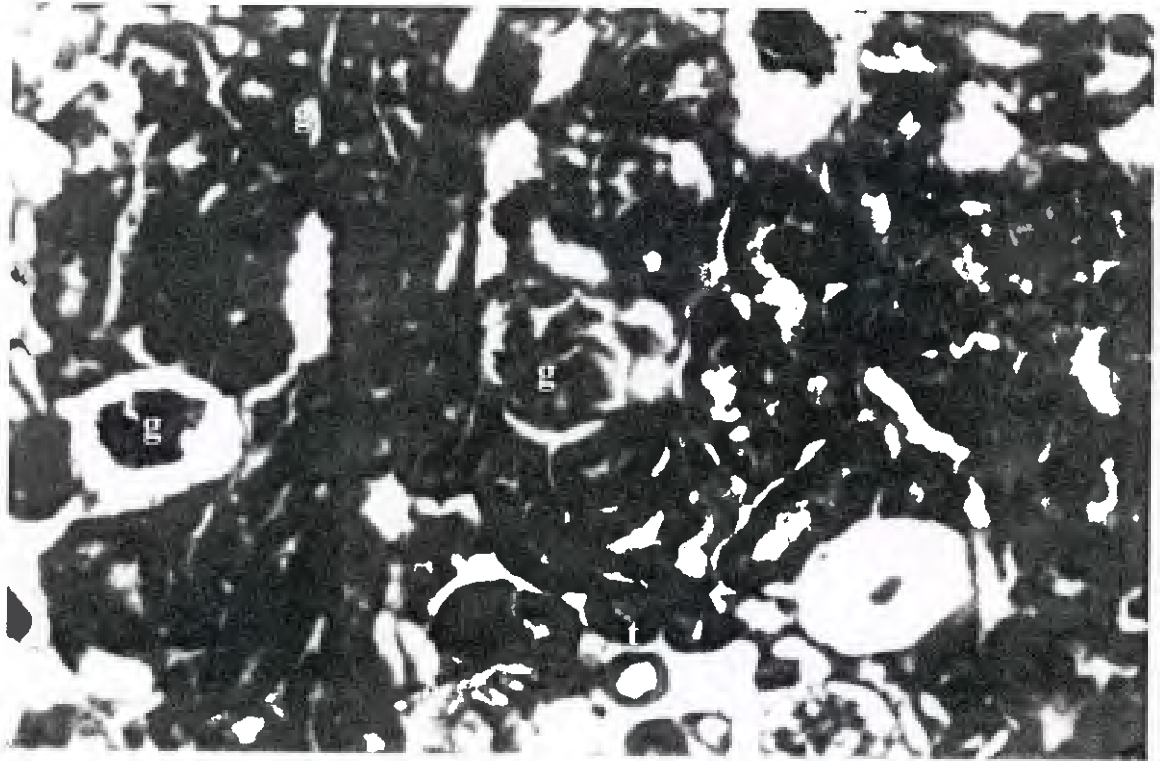


Fig.(13): A photomicrograph of a section of renal cortex of adult control rat showing :Normal glomeruli (g) and tubules (t) .Both glomeruli and tubules are surrounded by only minimal amount of loose connective tissue (e).
(Masson's trichrome X 200)

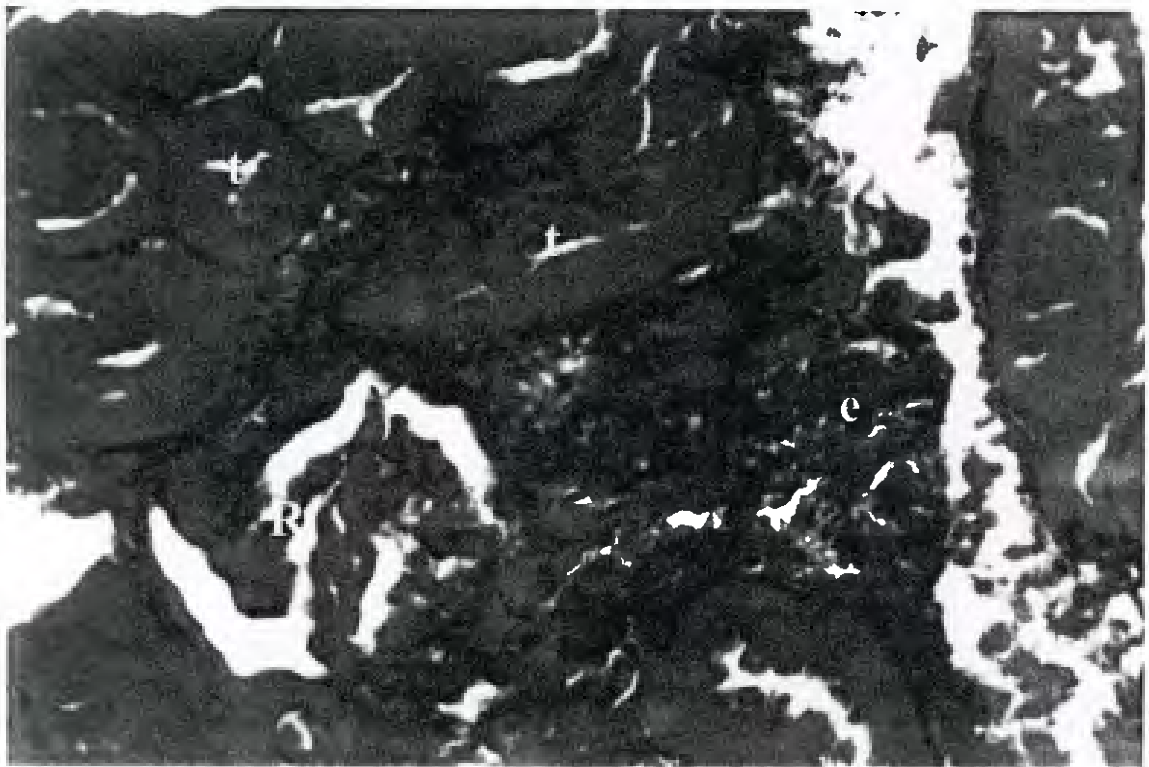


Fig.(14): A photomicrograph of a section of renal cortex of cyclosporine group showing :Marked amount of connective tissue (e) in the interstitium. This connective tissue surrounds the atrophic renal corpuscle (R) and the tubules (t).
(Masson's trichrome X 400)

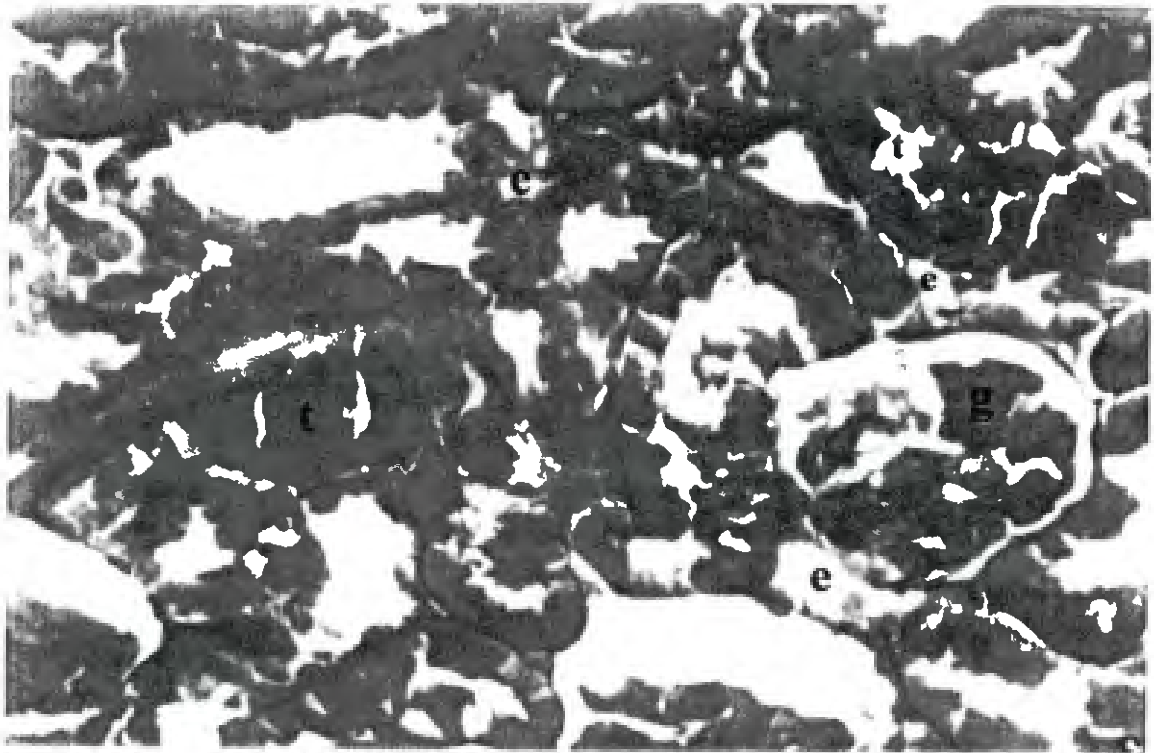


Fig.(15): A photomicrograph of a section of renal cortex of lacidipine group showing :Reduction of connective tissue (e) deposition in between the glomeruli (g) and tubules (t). (Masson's trichrome X 400)




Fig.(16) : An electron photomicrograph of a section of proximal convoluted tubule lining cells in renal cortex of adult control rat showing :The apical parts of the cells surround the lumen (L) .These cells have microvilli (mv) .Its nucleus is rounded with prominent nucleolus (nu) .Its cytoplasm contains mitochondria (M) , few vesicles (v) and small sized lysosomes (y) (X 3000)



Fig .(17): An electron photomicrograph of a section of proximal convoluted tubule lining cells in rat renal cortex of cyclosporine group showing: The apical parts of the cells have few numbers of microvilli (mv) Its cytoplasm contains different sizes of lysosomes (y) and large vesicle (v) .The lumen (L) contains large sized epithelial debris (d) and inflammatory cell (I) .

(X 3000)

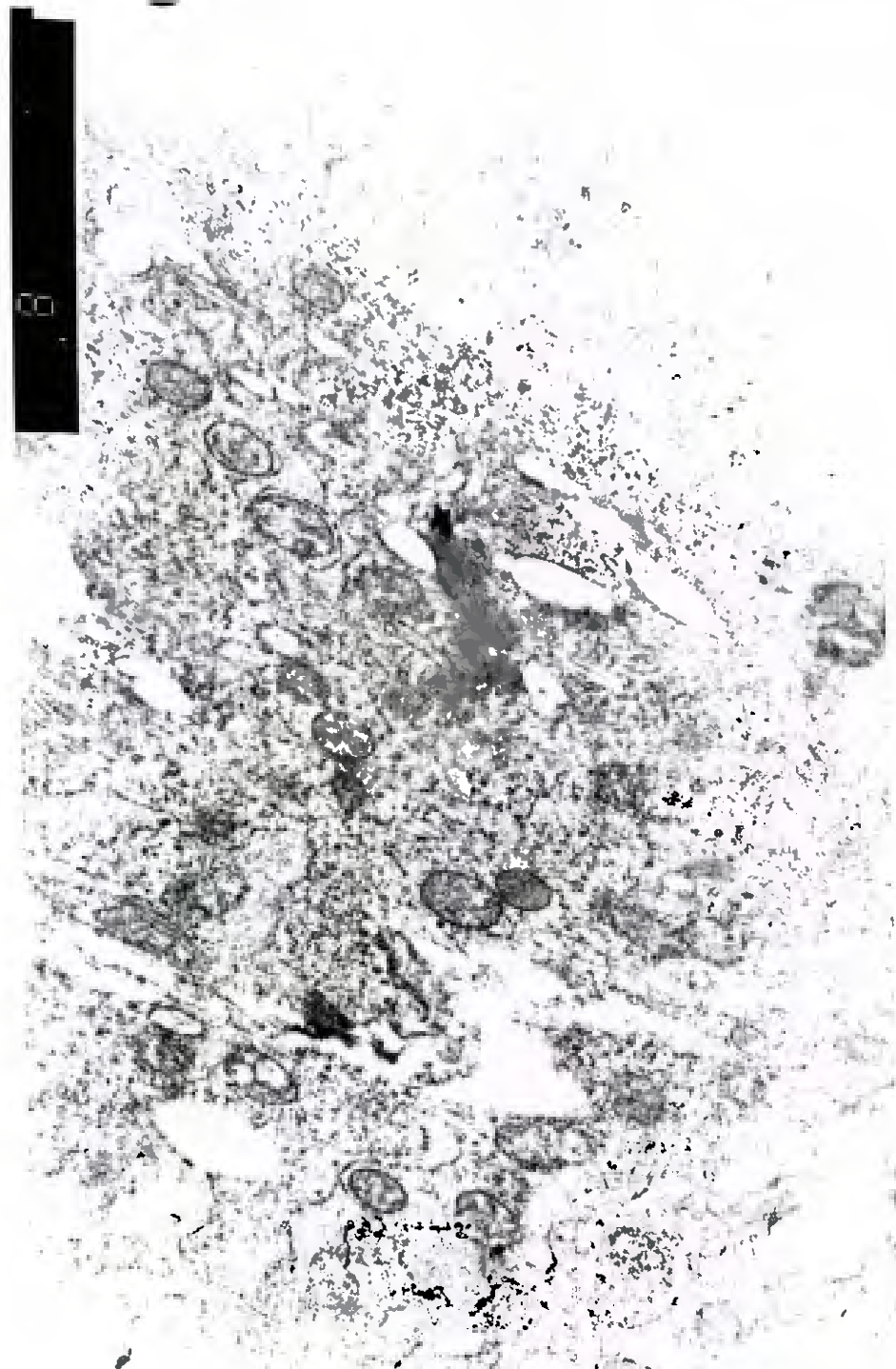


Fig .(18): An electron photomicrograph of a section of proximal convoluted tubule lining cells in rat renal cortex of cyclosporine group showing :The apical part of the cell contains many vacuoles (va)lysosomes (y) and degenerated mitochondria (dm) while others mitochondria are intact (IM). It shows damage to some microvilli (mv) which project inside the lumen(L).

(X 8000)

0024332330

Fig. (19): An electron photomicrograph of a section of proximal convoluted tubule lining cells in rat renal cortex of cyclosporine group showing: Partial degeneration of nuclei (dn) of its cell. The cytoplasm contains different sizes of lysosomes (y), vacuoles (va) and vesicles (V). (X 3000)


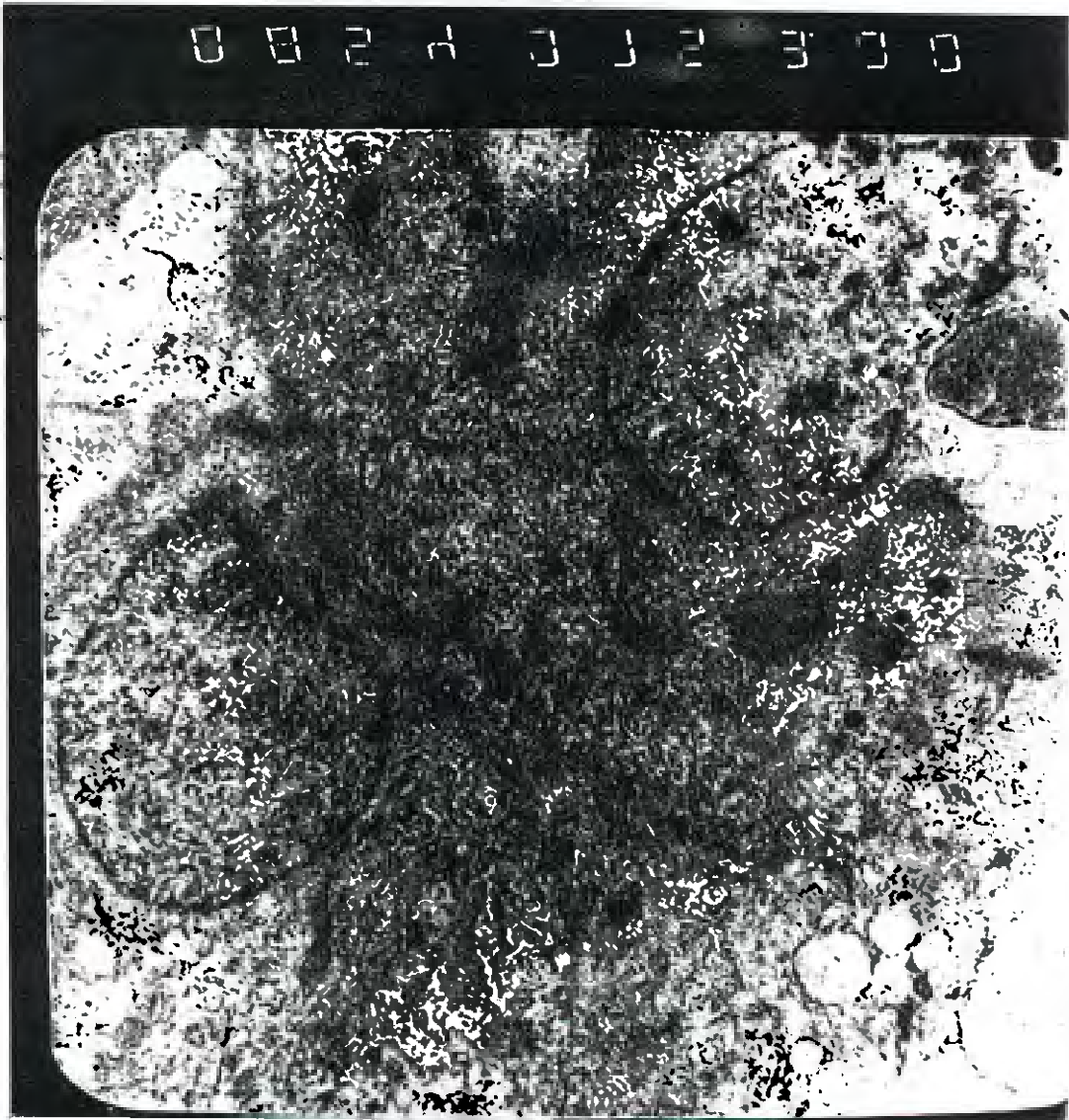


Fig.(20): An electron photomicrograph of a section of proximal convoluted tubule lining cells in rat renal cortex of lacidipine treated group showing: Normal appearance of microvilli (mv) and normal nucleus (N) with prominent nucleolus (nu). The cytoplasm contains mitochondria (M) and few lysosomes (y) and vesicles (v)

(X 3000)

DISCUSSION

The present study dealt with the normal structure and effect of cyclosporine on the renal cortex of adult rat. Also this study evaluate the protective effects of lacidipine in cyclosporine induced nephrotoxicity in rats. The cyclosporine is now used as the immunosuppressive drugs in human organ transplantation. However, the clinical use of cyclosporine is severely limited by nephrotoxicity (Rodicio, 2000). In the present study, the histopathological examination of renal sections demonstrated that the cyclosporine produced necrosis of some glomeruli, thickening of the Bowman's capsule and degeneration of some tubules. There were hyaline degeneration of other tubules and interstitial fibrosis. These results are similar to that reported by Keown and Stiller (1995), Shihab, et al (2000) and Rodicio (2000). Keown and stiller (1995) observed that chronic cyclosporine administration leads to loss of tubular epithelial cell integrity and tubular atrophy. Shihab, et al (2000) reported that chronic cyclosporine administration produced interstitial fibrosis and afferent arteriolar hyalinosis. Rodicio(2000) reported that chronic administration of cyclosporine induced vascular lesions in the endothelium, vacuolation and thickening of the basement membrane. On the other hand, Naidu, et al (1999), reported calcified concretions in the tubules with cyclosporine administration. In the present study, most of the organelles of the convoluted tubular cells are affected particularly mitochondria, lysosomes and microvilli of brush border. The cytoplasm of these cells contained increased number of dense lysosomes, many vacuoles and vesicles. Some of mitochondria are degenerated. There were partial damage of micovilli and partial degeneration of some nuclei. The lumen of the proximal tubule contained epithelial debris and inflammatory cells. These results are in agreement with the results of Keown and Stillar (1995). In the present study it was found that daily oral administration of cyclosporine at a dose of 50mg /kg produced significant elevation of blood urea and serum creatinine. These results are agreement with Whiting and Simpson (1988). They reported that the cyclosporine causes a dose-related decrease in renal function in experimental animal. It produced a significant increase in serum creatinine and blood urea. The mechanism by which the cyclosporine produced

structural and functional changes in the kidneys was examined by many authors. English, et al, (1987) reported that cyclosporine decreases renal blood flow by constricting the afferent arteriole proximal to the glomerulus. Also, Rodicio (2000) reported that the cyclosporine produced renal vasoconstriction and systemic hypertension. In the present study, it was observed that daily oral administration of lacidipine three days before and fourteen days along with cyclosporine significantly prevented cyclosporine induced elevation in blood urea and serum creatinine. Histopathological examination of renal sections of lacidipine treated group revealed marked improvement as no tubular atrophy, glomerular necrosis, thickening of the basement membrane or interstitial fibrosis. These findings are similar to the results of Naidu, et al (1999) who reported that lacidipine inhibited the increase in blood urea and serum creatinine induced by cyclosporine. Histologically, cut sections of kidney from lacidipine treated animals display only mild changes. Cyclosporine did not show any tubular or glomerular atrophy in animals pretreated with lacidipine. Recently, Fassi, et al (1999) observed that lacidipine, because of its predominant vasodilatory effect at the preglomerular level antagonizes the cyclosporine associated renal hypoperfusion.

Thus, it is suggested that lacidipine produces nephroprotective effect in the rat model of cyclosporine induced nephrotoxicity.

REFERENCES

1- Bond, G., DalPalu, C.; Hansson, L. (1993):

European Lacidipine study on Atherosclerosis (ELSA). J. Hypertens., 11 (suppl.5) : 405.

2- Borel, J.F.(1994):

Cyclosporine .In:Dale MM,Foreman,J.C,Fan.T.P (eds)Textbook of immunopharmacology,3rd ed.Blackwell scientific publications, Oxfor, ch29 Bray G.Liver failure induced by paracetamol.Avoidable deaths still occur.Br.Med.J.306:157-158.

3- Drury, R.A.B.and Wallington ,E.A.(1980):

Carleton's histological technique .5th edition Oxford university press .New yourk ,Toronto.p:131-135.

- 4- **English , J.; Evan, A.; Hoghton, D.C .and Bennett, W. M. (1987):**
cyclosporine .Induced acute renal dysfunction in the rat: Evidence of arteriolar vasoconstriction with preservation of tubular function. *Transplantation* , 44:135-144.

- 5- **Fassi,A.; Sangalli ,F.; Colombi,F;Perico, N.; Remuzzi, G. and Remuzzi, A.(1999):**
Beneficial effects of calcium channel blockade on acute glomerular hemodynamic changes induced by cyclosporine. *Am. J. Kidney. Dis.* Feb; 33(2):267-275.

- 6- **Flavio, V. and William , J. C. (1983):**
Long term renal function in kidney donors ,*Transplantation* .vol. 36 No.6:p.626.

- 7- **Horbin .R. W. and Bancroft, J. D.(1998):**
Trouble shooting, *Histology stains*.Churchill livingstone. New York, Edinburgh,London,PP:88-93,218-221.

- 8- **Hyat, M. A. (1986) :**
Preparation of the tissue for E/M studies. In: *Basic techniques for transmission electron microscopy*. Edited by M. H. Hyat, chapter 4. Academic press Inc. Tokoyo, Toronto. Pp. 10-230.

- 9- **Keown,P.AandStiller ,C.R.(1995):**
Cyclosporine– allograft rejection, in Massry S. G, Glassock ,R. J. (eds): *Textbook of nephrology*,ed2.Battimore, Williams and Wilkins, Vol. 2, PP.1648-1655.
- 10- **Keown ,P.A.;stiller ,C.R.and Wallance,A.C.(1992):**
The nephrotoxicity of cyclosporine A; in williams M, Burdick, J. Salez K(eds):*Kidney Transplant Rejection :Diagnosis and Treatment* ,ed.2.

- 11- **Krenek ,P.; Salomone, S.; Kyselovic, J.; Wibo, M; Morel, N.and Godfraind, T.(2001):**
lacidipine Prevents endothelial dysfunction in salt loaded stroke prone hypotensive rats .*Hypertenion*,Apr;37(4):1124-1128.
- 12- **Myers ,B.D.(1986):**
Cyclosporine nephrotoxicity - *Kidney Int.*30:964-974.

- 13- **Naidu ,M.U.R.;Kumar,K .V .and Shifow ,A. A. (1999):**
Lacidipine protects agiants cyclosporine-induced nephrotoxicity in rats
*Nephron.*81:60-66.

- 14- **Perico ,N.and Remuzzi,G.(1991):**
cyclosporine – induced renal dysfunction in experimental animals and humans.
*Transplant Rev.*5:63-80.

- 15- Perico , N; Ruggenti, P. Gaspari, F;Mosconi, L. Benigni, A.(1992):**
Daily renal hypoperfusion induced by cyclosporine in patients with renal transplantation. *Transplantation*, 54:56-60.
- 16- Rodicio ,J.L(2000):**
Calcium antagonists and renal protection from cyclosporine nephrotoxicity. *J. Cardiovasc. Pharmacol.* 35 (suppl.1) : 7-11.
- 17- Rodicio,J.L;Morales,J.MandAlcazar,J.M.(1993):**
calcium antagonists and renal protection .*J. hypertens* 11(suppl.1):49-53.
- 18- Rooth ,p.Davidson,1;Diller,K.andTalijedab ,I,B.(1987):**
Beneficial effects of calcium antagonist pretreatment and albumin infusion on cyclosporine A. induced impairment of Kidney microcirculation in mice. *Transplant Proc*;19:3602-3605.
- 19- Salvi ,S.,Rizzini.P.and Calabrese ,G(1990):**
Farmacocinetica di un nuvo calcio- antagonista ,oncedaily ,a lunga durata d'azione, Lacidipina, in pazienti con insufficienza renale :confronto con soggetti sani .XXXI congresso Nazionale della societa Italiana di Nefrologia , Siena ,May.
- 20- Shihab ,F.S. .;Yi,H.;Bennett,W, M. and Andoh,T.F.(2000):**
Effect of nitric oxide modulation on TGF-beta 1 and matrix proteins in chronic cyclosporine nephrotixicity. *Kidney-int.sep.*58(3):1174-1185.
- 21- Whiting,P.H.and simpson, J, G.(1988):**
Lithium clearance measurements as an indicator of cyclosporine A nephrotoxicity in the rat .*Clin.sci*;74-:173-178.